

# AXIAL LOADING OF THE LUMBAR SPINE IN CT SCANNING

## A valuable complement in the diagnosis of central spinal stenosis

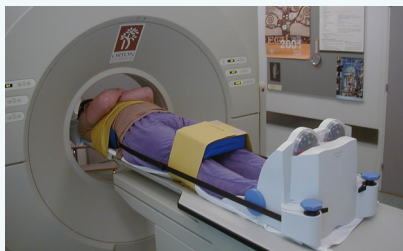

Fig. 1. Compression CT-scanning with DynaWell™ device

Kaj Tallroth, MD, PhD, FICA, ORTON Orthopaedic Hospital, Finland  
Karl-August Lindgren, MD, PhD, ORTON Rehabilitation, Finland  
Jan Willén, MD, PhD, Sahlgrenska University Hospital, Sweden

### Objectives

To assess the diagnostic aid of axial loading of the lumbar spine in CT scanning compared to conventional CT examination in the evaluation of lumbar spinal stenosis.

### Axial Loading technique

Both MR and CT are performed with the patient lying in the scanner when the compression load is only about 25%, as compared with the spinal load in a standing position. Myelograms can be taken in an upright position but does not provide cross-sectional images of the dural sac, which is valuable in the diagnosis of central spinal stenosis (1).

A new portable device, DynaWell™, which facilitates compression of the lumbar spine and simulates the normal pressure exerted when standing has recently been introduced by J. Willén, B. Danielson and coworkers (2,3). They have reported good clinical results with this method using MR and CT-Myelography examinations.

### Patients and methods

One hundred consecutive patients, referred from ORTON Rehabilitation to CT examination due to chronic lower back problems and clinical symptoms suggesting spinal stenosis, were investigated. There were 45 women and 55 men, aged 25 to 59 years (mean 48).

The patients underwent ordinary CT scanning completed with a complementary compression examination. For the latter, a harness was strapped over their shoulders and upper chest. Two straps attached this vest to the DynaWell™ compression device (fig. 1). By tightening the straps, the pulling load (appr. 50% of the body weight or max 35 kp) was adjusted to simulate the compression of the dural sac when standing. In the 100 patients, 300 disc levels were available for examination.

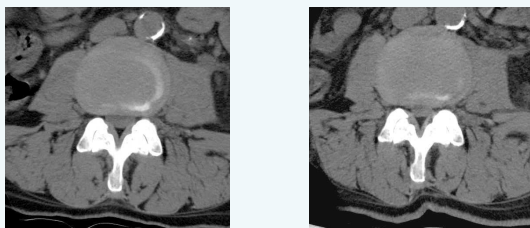

Fig. 2. CT scans of a patient with and without compression

With a software program on Picker PQ2000 CT scanner, the area of the dural sacs was measured both at the ordinary CT and the compression examination. The cross sectional areas were classified as follows: >100mm<sup>2</sup> = normal, 100 - 75mm<sup>2</sup> = relative spinal stenosis, and <75mm<sup>2</sup> = absolute spinal stenosis (4,5).

### Results

In almost every patient and at every disc space the area of the dural sac diminished in compression (fig. 3). In L5-S1, the spinal canal was widest, the size of the dural sac varied the most and the effect of the compression was smallest.

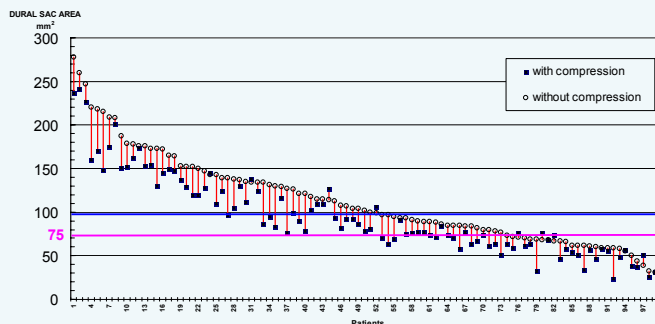


Fig. 3. Reduction of the dural sac at L4-5 disc level in 100 patients

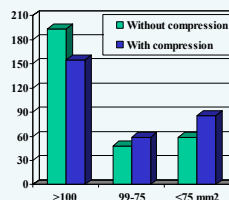


Fig. 4. Compression effect on the dural sac area at the 3 lowest disc levels

Of the 300 examined disc levels, in 193 the dural sacs were normal without compression whereas with compression only 155 were normal. Absolute stenosis appeared at 59 levels before compression and at 86 levels with compression (fig. 4).

Only 20 patients had stenosis at one disc level only. Stenosis at two or three levels was more frequent (fig. 5).

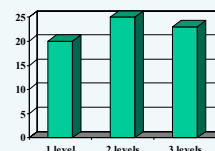


Fig. 5. Number of stenotic levels

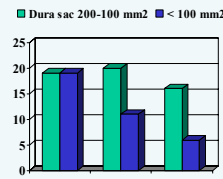


Fig. 6. Average reduction of dural sac area at compression

In L3-4 space normal and stenotic dural sacs diminished to the same extent (appr. 19 mm<sup>2</sup>). In L4-5 and L5-S1 the normal sized dural sacs decreased more than the stenotic ones (fig. 6).

Of the 100 patients 26, experienced their everyday back discomfort or slight pain during the compression study. Moderate pain was felt by 8 patients and severe pain by 5 patients. In 2 patients, the pain lasted more than 30 min. No one got any objective symptoms.

### Conclusions

Using a plain CT examination in conjunction with a complementary compression examination combines the advantages of weight-bearing myelography and cross-sectional imaging. For many of the patients with central stenosis, the diagnosis was established only with the compression examination and the findings were thus in accordance with the patients' symptoms. The method is non-invasive, fast and inexpensive.

### References

- Schönström N et al. Spine 10 (1985) 806-11
- Willén J et al. Spine 22 (1997) 2968-76
- Danielsson B et al. Acta Radiol 29 (1998) 604-11
- Schönström N et al. Spine 13 (1988) 385-8
- Schönström N et al. Spine 9 (1984) 604-7